



Modeling of Mandibular Fractures of Non-Firearm Origin

Belikov O.B., Roshchuk O.I., Belikova N.I., Sorokhan M.M., Aliyev V.I.

d.m.s., prof.

c.m.s., as.prof.

c.m.s., as.prof.

*Bukovinian State Medical University, m. Chernivtsi, Ukrainian, Theater square 2, 58002
Nakhichevan State University, Nakhichevan, Azerbaijan)*

Date of Submission: 01-07-2025

Date of Acceptance: 10-07-2025

ABSTRACT: The article summarizes the results of clinical and experimental studies of the formation of mandibular fractures of non-gunshot origin depending on the direction and angle of impact, the features of destruction of its surface during jaw clamping and unclamping. Objective of the study. To conduct an experimental reproduction of mechanical blunt trauma of the mandible, to document the localization of fractures and to determine the potential relationship between the site of impact and the site of fracture to determine the nature of bone destruction depending on both the direction of impact and the state of functioning of the jaws. As a result of the study, a clear pattern was established: fractures were formed either in the area of impact to the mandible or in the area adjacent to the impact site; depending on the impact site, the number of fractures that occurred as a result of impact varied; in no case did impact to the same area cause exactly the same set of fractures, and the location of fractures that occurred at points other than the impact site also varied significantly; In terms of the structural geometry of the mandible, fractures consistently occurred in areas recognized as biomechanically weak, including the necks of the articular processes, corners, and mental foramina; when the jaws are closed, direct compression fractures are formed on the outer surface of the jaw, and tensile fractures on the inner surface, where the primary fracture is formed, and a bone fracture zone is formed at the point of direct contact; when the jaws are open, indirect fractures are formed on the opposite side.

Keyword: mandible; anatomical features; non-gunshot fracture; localization; displacement of fragments.

I. INTRODUCTION.

A mandibular fracture can occur in any part of the jaw, as it has a complex architectural configuration and is an arched structure. Depending on the localization of the fragments, mandibular

fractures can be single, double, and triple [1, 2, 3, 7]. When analyzing the frequency of localization of mandibular fractures, it is possible to establish the prevalence of traumatic damage to the mental area (43.05%) and the angle (31.79%) of the mandible in patients of both sexes. At the same time, single (52.17%) and double (47.46%) fractures of the mandible prevailed in men, and double (47.46%) fractures in women. Multiple mandibular fractures were 4.3 times more common in women than in men. The most common types of mandibular fractures were transverse and oblique (31.63% and 40.92%), and the least commonly diagnosed were comminuted (6.65%) fractures of the mandible [4, 5].

As a rule, single fractures of the mandible are localized between the second and third molars, in the area of the corners, articular processes, between the lateral incisors and canines. Double - mostly occur in the area of the canine and articular process, canine and angle of the lower jaw, premolars and angle of the lower jaw. Triple fractures are most often localized in both articular processes and between the central incisors. Fractures occur both when the jaws are closed and when they are opened ⁶.

Effective restoration of facial aesthetics and function requires accurate assessment, diagnosis, and treatment of mandibular fractures.

A significant number of retrospectives, clinical and experimental studies have been conducted. According to the results of retrospective studies, it has been established that fractures of various types have certain causes. The causes of mandibular fractures include road traffic accidents, assaults, domestic violence, falls, sports and workplace injuries, ballistic trauma, and pathological fractures [7, 8, 9, 10, 11]. The etiology and severity of mandibular fractures can also be classified by age, gender, socioeconomic status, and mechanism of injury. The disadvantages of retrospective studies include the fact that the



conditions of impact are mostly unknown, as a patient presenting with a mandibular fracture may not know the exact location, angle, and force of impact.

Clinical studies have the advantage of establishing a link between the type of mandibular fracture and forensic trauma scenarios [12, 13, 14, 15, 16, 17]. However, in clinical studies, the exact loading conditions that affect fracture patterns are unknown, while biomechanical endurance studies have limited information on fracture patterns [25, 26, 27].

While retrospective and clinical studies provide an opportunity to control the impact conditions and directly analyze the fracture and its consequences, experimental studies provide observation of the fracture formation process. There is also inconsistency in the description of impact sites. Thus, different authors point to the body of the mandible [20, 21, 22, 23], the angle of the mandible [21, 24], and the articular process [21, 27], which makes it difficult to compare the results of studies performed using different experimental models.

To correctly determine the number and location of impacts in blunt trauma to the human mandible, understanding the relationship between impact site and fracture pattern is crucial to accurately determine the number and location of impacts. However, this basic experimental data on mandibular fractures is limited.

Thus, previous studies have identified the location, impact force, and fracture pattern of mandibular fractures. However, the direction of impact at the same point, as well as the nature of the bone fracture depending on its surface and the type of fracture during jaw closure and opening have not been investigated.

Objective of the study. To conduct an experimental reproduction of mechanical blunt trauma of the mandible, to record the localization of fractures and to determine the possible relationship between the place of impact and the place of fracture to determine the nature of bone destruction depending on the direction of impact and the state of jaw functioning.

II. MATERIALS AND METHODS.

To conduct an experimental reproduction of mechanical blunt trauma of the mandible, to document the localization of fractures and to determine the potential relationship between the site of impact and the site of fracture to determine the nature of bone destruction depending on both the direction of impact and the state of functioning

of the jaws.

The material for the experimental model was 11 intact, embalmed human head specimens obtained from male cadavers, each of whom was 45-50 years old at the time of death. The skulls were scanned with a computed tomography scanner before being opened and impacted. Only samples without serious ante-mortem injuries or pathologies were selected for the study. Prior to the study, the samples were stored at -20 °C and completely thawed at room temperature. Such storage conditions allow bone tissue to maintain its biomechanical properties in vivo [22].

The tests were designed to simulate a blow to an upright skull with unrestricted post-impact movement [20]. A specially manufactured pneumatic system was used to deliver impacts [20, 21] (Fig. 1).

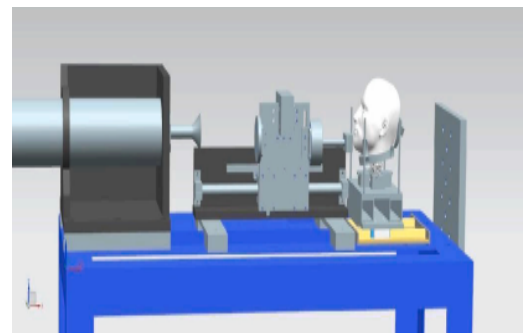


Figure 1. Display of a customized pneumatic system in preparation for a midline impact on the mandible[21].

The system controlled the release of compressed nitrogen gas to impart initial velocity to the guide carriage that held the impactor. Based on the study²⁰, the experimental setup with a mass of 6-7 kg received an initial velocity of 5 m/s and ensured the creation of a skull fracture. Additionally, the pneumatic system was calibrated and the impact pressure was correlated with the initial velocity before conducting impact tests of the mandible[21]. In this study, all mandibular impact tests used a pressure of 80 PSI to simulate fracture formation at a speed of 5 m/s. In all experiments, the head was positioned so that the impact surface was vertical to the impact site. The mass of the impact was calculated as consisting of the mass of the impactor and the guide carriage that held the impactor.

Combining these parts together, the total impact mass was 6.5 kg, as suggested by previous researchers for skull fractures [20, 21]. Impacts were applied at 5 points in the mandible: midline (n = 3), anterior body (n = 2), middle body (n = 2),

posterior body (n = 2), and jaw branch with processes (n = 2) (Fig. 2).

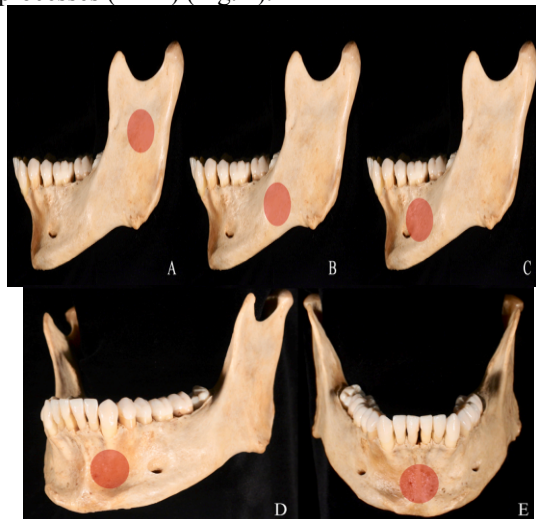


Figure 2. Impact zones of the mandible. From left to right[20, 21].

As can be seen from Fig. 2, the impact sites of the mandible were divided into 5 zones: zone (A) included the branch and processes, the jaw body was divided into four zones: posterior (B), middle (C), anterior (D), and medial (E), and the impact site was marked with a red circle.

The following landmarks were used to standardize the localization of impacts [21]: midline (center of the chin protuberance), anterior part (teeth 33, 32), middle part (teeth 35, 36), posterior part (teeth 37 or 38, if present), and branch area (between the mandibular notch and the angle). For each of the described areas, the localization of the impact was the center of the alveolar bone.

After the impact, the mandible was dissected and cleaned of soft tissue residue by maceration in warm water[19].The mandible was carefully dissected manually, and then all fragments were placed in a gauze bag and macerated in hot water [20].

All bone surfaces were carefully inspected for complete and incomplete fractures, which were then manually mapped on a standardized map. To account for differences in the nature of fractures on each surface, internal and external diagrams of the mandible were created.

Each specimen was analyzed for the following characteristics: number of fractures produced by each impact; anatomical location of each fracture; and fracture completeness. The location of fractures was assessed using the classification scheme developed by the AOCMF (Fig. 3)[23, 24].

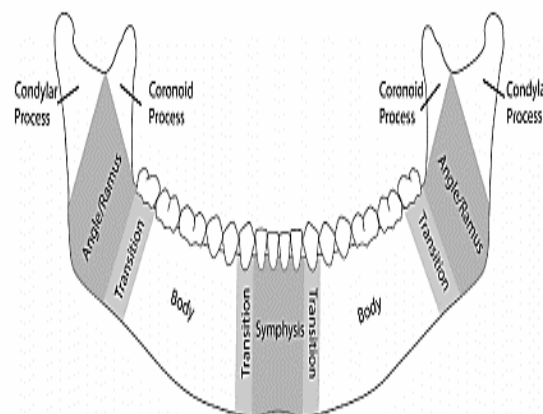


Figure 3. Nine mandibular areas and four transition zones according to the AOCMF definition [23, 24].

This scheme was chosen due to its clinical relevance and clear definitions, including a visual representation of the mandibular regions. It identifies nine areas of the mandible: left and right articular processes, left and right coronal processes, left and right jaw angle, left and right body and symphysis. AOCMF also identifies anterior transition zones between the body and symphysis and posterior transition zones between the body and angle.

Results of the study.

All blows to the mandible resulted in fractures. The impacts were delivered with an average initial velocity of 7.8 ± 1.4 m/s, which corresponds to an average input energy of 201.3 ± 69.5 J. Given that energy is the product of mass and velocity, and the velocity could not be precisely controlled, the actual values of the input energy varied. The test resulted in 25 fractures in seven of the nine AOCMF zones of the mandible. The only zones in which no fractures were detected were the right angle and the right coronal process.

Thus, the most commonly fractured areas of the mandible were the mandibular body (9 fractures), followed by the condyles (7 fractures), symphysis (5 fractures), angle (3 fractures), and coronoid (1 fracture). The results are shown in Table 1.



Table 1 - Data from mandibular impact tests (n = 11): information on fracture locations

Sample	Value location	Number of fractures	Fracture Locations
1	Midline	5	Left and right articular processes; left and right body; symphysis
2	Midline	4	Right body; symphysis; left coronoid process; left articular process
3	Midline	3	Left and right articular process; symphysis
4	Anterior body	2	Right articular process; left anterior transition zone (left body)
5	Anteriorbody	1	Left body; left corner
6	Mid-Body	1	Left body
7	Mid-Body	1	Left angle
8	Posteriorbody	1	Left posterior transition zone (left corner)
9	Posteriorbody	2	Left corner; symphysis
10	Ramus	3	Right body; left anterior transition zone (symphysis); left articular process
11	Ramus	2	Left anterior transition zone (left body); left articular process

Table 1 shows that most fractures occurred along the midline. They differed in the number of fracture lines and the formation of direct and indirect fractures. For example, one of the samples had five fracture sites: a fracture of the head of the right articular process; a vertical fracture of the right body at the level of 41.42 teeth with branched incomplete fractures inside and outside, a vertical symphyseal fracture with branched incomplete fractures inside; a vertical fracture of the left body at the level of 31.32 teeth; a fracture of the head of the left articular process.

The second most frequently injured area was the mandible. All two blows in the area of the left coronoid process caused left submandibular fractures near the site of impact. However, they were anatomically inferior to the fractures caused by blows to the midline and extended backward below the mandibular notch. There was a horizontal fracture of the left articular process with branching outward and a horizontal fracture of the coronoid process with branching of incomplete fractures inward. An indirect fracture of the mandible body on the right was also recorded.

The third most frequent fractures are blows to the mandible body from behind. In both cases, fractures were recorded in the left posterior part of the mandible in the area of the left mandibular angle. A symphyseal fracture was also diagnosed. In this case, there were incomplete

fractures with fragments on both the inner and outer surfaces.

The fourth place was taken by fractures caused by a blow to the anterior mandible. All of the blows to the left front of the body resulted in fractures on the left side: a fracture approximately at the point of impact; a fracture of the right mandible on the right and a vertical fracture on the left side of the body at the level of the canine.

As a result of the impact, only one fracture occurred on the left side of the mandible body to the middle of the body: a left angular fracture extending from the top of the canine to the left corner below. This fracture was incomplete internally and had branches.

III. DISCUSSION.

It is well known that the mandible has an arched shape. In the area of the corners, molars, branches, and the base of the articular processes, its cross-section is thin, and in the anteroposterior direction in the same areas it is quite significant [6]. Therefore, during a lateral impact, a fracture in these areas can occur from a small force.

The canine area is the place of least resistance of the lower jaw only in a lateral impact. In a front-to-back impact, the area of the upper articular process is the weakest point. In case of lateral impacts, fractures occur here quite rarely and have an oblique direction - from top to bottom,



from the inside to the outside. The place of their localization is at the base of the articular process.

The direction of impact has a significant impact on fracture localization. Thus, when struck from the front to the back and from the side, the articular processes (base and neck), the corners of the lower jaw and the sockets of the last molar and canine have the least resistance.

When impacted from the front, the horseshoe shape of the mandible results in the acting force being decomposed into two components [26, 25]. In this case, the articular processes take half the load and are rarely damaged. Thus, when a force is applied to the mandible in the lateral direction, both direct and indirect fractures are observed.

The nature of the fracture is also affected by the state of the masticatory muscles at the time of impact (closed or open jaws) [27]. Most often, direct fractures occur as a result of a blunt object hitting the body of the mandible (its lateral section) with the jaws closed. In this case, the outer surface of the jaw is compressed at the point of application of force, and the inner surface is stretched, where a primary tear is formed, and the bone fracture zone is formed at the point of direct contact. This results in transverse, oblique, or comminuted fractures [6].

If the blow is delivered from the side and bottom, the zone of bone destruction shifts to the lower edge of the jaw, and the zone of fracture, on the contrary, to its upper edge. An oblique fracture occurs when a blow is delivered from the side to the lower part of the mandible. Often, a comminuted fracture occurs at the level of the canine when the blow is delivered from the side, closer to the chin projection and downward. It was not possible to simulate the development of a double comminuted fracture in the area between the canines. This specific fracture occurs when a wide area of the traumatic agent's surface strikes the chin area, where the mandible is the least strong [6].

A strong sharp blow to the chin area with the jaws open from the front and from top to bottom results in a very interesting picture. In this case, there are two symmetrical fractures at the level of the second and third molars, as well as a fracture of the neck of the articular processes on one or both sides.

During a lateral impact to the mandible body, a single fracture is observed with signs of bone stretching on the inner surface and compression on the outer surface of the bone. At the same time, due to the bending mechanism, a fracture was observed on the opposite side at the

level of the canine and first premolar. Additionally, on the opposite side, at the point of application of force, there is a fracture of the neck of the articular process.

In case of impact on the angle of the mandible, two fractures are observed on the side of the injury: the first one is at the point of direct application of force (due to extension), and the second one is at the level of the lateral incisor and canine (due to the flexion mechanism).

In the mechanism of injury to the mandible, its location relative to the maxilla is important [26, 27]. For example, closed jaws ensure its relative immobility, which depends on both tooth contact and the type of bite. When struck from the side, the lower jaw is directly affected by the impact. These conditions determine 2 types of mandibular injuries: [6].

1. When the jaws are closed, the upper and lower dentition provide fixation of the jaws, which leads to the absence of lateral displacement of the lower jaw. The damage occurs on one side, where a bone fragment is formed, or a compact substance "crumbles" in the case of non-displaced fractures.

2. With open jaws, the chin part rotates in the direction of external action relative to the articular processes, which are the fulcrum. As a result, the fracture occurs in the neck area, but on the opposite side. Under the influence of a significant force, it also occurs on the side of the acting force.

According to this mechanism, injuries of the lower jaw can also occur with closed jaws, but in the absence of teeth.

In the case of impacts to the angle of the mandible, the fracture of its body at the level of the lateral incisor and canine is observed on the opposite side, not on the side where the force is applied. In case of impact to the chin area (or to the side of it), the articular processes and the alveolar part of the mandible body are damaged.

IV. CONCLUSIONS.

As a result of the study, a clear pattern was established: fractures were formed either in the area of impact to the mandible or in the area adjacent to the impact site; depending on the impact site, the number of fractures that occurred as a result of impact varied; in no case did impact to the same area cause exactly the same set of fractures, and the location of fractures that occurred at points other than the impact site also varied significantly; In terms of the structural geometry of the mandible, fractures consistently occurred in areas recognized as biomechanically weak, including the necks of



the articular processes, corners, and mental foramina; when the jaws are closed, direct compression fractures are formed on the outer surface of the jaw, and tensile fractures on the inner surface, where the primary fracture is formed, and a bone fracture zone is formed at the point of direct contact; when the jaws are open, indirect fractures are formed on the opposite side.

Based on this pattern, practitioners can compare fractures in forensic cases to answer the question of whether a blow in one place can cause a fracture in another place, or whether a single blow can explain all the fractures seen in the mandible. Thus, in the diagnosis of mandibular fractures, it is important to consider not only the site of least resistance, but also the direction and location of the direct impact, as well as its location in relation to the maxilla.

REFERENCES

- [1]. Boffano P., Kommers S. C., Karagozoglu K. H., Gallesio C., Forouzanfar T. (2015). Mandibular trauma: a two-centre study. *International journal of oral and maxillofacial surgery*, issue 44, vol.8, pp. 998–1004.
DOI: 10.1016/j.ijom.2015.02.022
- [2]. Bormann, K. H., Wild, S., Gellrich, N. C., Kokemüller, H., Stühmer, C., Schmelzeisen, R., & Schön, R. (2009). Five-year retrospective study of mandibular fractures in Freiburg, Germany: incidence, etiology, treatment, and complications. *Journal of oral and maxillofacial surgery: official journal of the American Association of Oral and Maxillofacial Surgeons*, issue 67, vol. 6, pp.1251–1255.
DOI: 10.1016/j.joms.2008.09.022
- [3]. Carvalho, T. B., Cancian, L. R., Marques, C. G., Piatto, V. B., Maniglia, J. V., & Molina, F. D. (2010). Six years of facial trauma care: an epidemiological analysis of 355 cases. *Brazilian journal of otorhinolaryngology*, issue 76, vol. 5, pp. 565-574.
DOI: 10.1590/S1808-86942010000500006
- [4]. Rashid, A., Eyeson, J., Haider, D., van Gijn, D., & Fan, K. (2013). Incidence and patterns of mandibular fractures during a 5-year period in a London teaching hospital. *The British journal of oral & maxillofacial surgery*, issue 51, vol. 8, pp. 794-798.
DOI:https://doi.org/10.1016/j.bjoms.2013.04.007
- [5]. Matsyuk D., Kuzniak N. (2024). Clinical analysis of the location, nature and type of mandibular fractures in patients on admission to hospital *Intermedical journal*, vol. 1, pp. 134-139.
DOI: 10.32782/2786-7684/2024-1-21
- [6]. Mihajlichenko B.V., Bilyakov A.M., Franchuk V.V. (2024). *Sudovostomatologiya [Judicial dentistry]: pidruchnik. K.: VSV «Medicina»*. 263 p.
ISBN 978-617-505-977-7
- [7]. Jung, H. W., Lee, B. S., Kwon, Y. D., Choi, B. J., Lee, J. W., Lee, H. W., Moon, C. S., &Ohe, J. Y. (2014). Retrospective clinical study of mandible fractures. *Journal of the Korean Association of Oral and Maxillofacial Surgeons*, issue 40, vol. 1, pp. 21-26.
DOI: 10.5125/jkaoms.2014.40.1.21
- [8]. Kaura, S., Kaur, P., Bahl, R., Bansal, S., & Sangha, P. (2018). Retrospective Study of Facial Fractures. *Annals of maxillofacial surgery*, issue 8, vol. 1, pp. 78-82.
DOI: 10.4103/ams.ams_73_17
- [9]. Ali Ghalib Mutar Mahdi, Issam Abdul Aziz Ali(2013). A retrospective analytic study of mandibular fracture patterns in two different periods in Baghdad, *Journal of Oral and Maxillofacial Surgery, Medicine, and Pathology*, issue 3, vol. 25, pp. 205-209
DOI: 10.1016/j.ajoms.2012.08.006
- [10]. Fang, C. Y., Tsai, H. Y., Yong, C. Y., Ohiro, Y., Chang, Y. C., & Teng, N. C. (2023). A 10-year retrospective study on mandibular fractures in Northern Taiwan. *Journal of dental sciences*, issue 18, vol. 3, pp. 1330–1337.
DOI: 10.1016/j.jds.2023.04.010
- [11]. Brechlychuk P.P., Goncharuk-Khomyn M.Y. (2019). Estimation of the mandible fracture pattern according to retrospective studies with a large amount of studied samples. *Clinical dentistry*. vol. 1, pp. 11-18
DOI: 10.11603/2311-9624.2019.1.10142
- [12]. Subhashraj, K., Ramkumar, S., & Ravindran, C. (2008). Pattern of mandibular fractures in Chennai, India. *The British journal of oral & maxillofacial surgery*, issue 46, vol. 2, pp. 126–127.
DOI: 10.1016/j.bjoms.2006.10.004
- [13]. Sinha, V., Chaudhary, N., Jha, S. G., Chaudhari, N. P., & Rathva, K. R. (2022). Management of Maxillofacial Trauma in Road Traffic Accident (RTA) at Tertiary Care Center. *Indian journal of otolaryngology and head and neck surgery: official publication of the Association of*



- Otolaryngologists of India, issue 74, vol. 2, pp. 1246-1252.
DOI: 10.1007/s12070-020-02299-6
- [14]. Unnewehr, M., Homann, C., Schmidt, P. F., Sotony, P., Fischer, G., Brinkmann, B., Bajanowski, T., & DuChesne, A. (2003). Fracture properties of the human mandible. *International journal of legal medicine*, issue 117, vol. 6, pp. 326-330.
DOI: 10.1007/s00414-003-0391-6
- [15]. Panesar, K., & Susarla, S. M. (2021). Mandibular Fractures: Diagnosis and Management. *Seminars in plastic surgery*, issue 35, vol. 4, pp. 238-249.
DOI: 10.1055/s-0041-1735818
- [16]. Farzan, R., Farzan, A., Farzan, A., Karimpour, M., & Tolouie, M. (2021). A 6-Year Epidemiological Study of Mandibular Fractures in Traumatic Patients in North of Iran: Review of 463 Patients. *World journal of plastic surgery*, issue 10, vol. 1, pp. 71-77.
DOI: 10.29252/wjps.10.1.71
- [17]. Shetty, V., Atchison, K., Der-Matrosian, C., Wang, J., & Belin, T. R. (2007). The mandible injury severity score: development and validity. *Journal of oral and maxillofacial surgery: official journal of the American Association of Oral and Maxillofacial Surgeons*, issue 65, vol. 4, pp. 663-670.
DOI: 10.1016/j.joms.2006.03.051
- [18]. Yunus, A. D., Gultom, F. P., Puspitawati, R., Sari, F. A., Prastyo, E., Rijaldi, F., & Suropto, S. (2024). Dental Profiling and Findings of Multiple Jaw Fractures in Traffic Accident Victim: A Case Report. *E-GiGi*, issue 12, vol. 2, pp. 246-252.
DOI: 10.35790/eg.v12i2.53455
- [19]. Fenton, T. W., Birkby, W. H., & Cornelison, J. (2003). A fast and safe non-bleaching method for forensic skeletal preparation. *Journal of forensic sciences*, issue 48, vol. 2, pp. 274-276.
PMID: 12664982
- [20]. Isa, M. I., Fenton, T. W., Goots, A. C., Watson, E. O., Vaughan, P. E., & Wei, F. (2019). Experimental investigation of cranial fracture initiation in blunt human head impacts. *Forensic science international*, vol. 300, pp. 51-62.
DOI: 10.1016/j.forsciint.2019.04.003
- [21]. Goots, A., Isa, M. I., Fenton, T. W., Wei, F. (2022). Blunt force trauma in the human mandible: An experimental investigation. *Forensic Science International* 5 100252
DOI: 10.1016/j.fsi.2021.100252
- [22]. Kaye B., Randall C., Walsh D., & Hansma P. (2012). The effects of freezing on the mechanical properties of bone, *Open Bone J.*, vol. 4, pp. 14-19.
DOI: 10.2174/1876525401204010014
- [23]. Cornelius, C. P., Audigé, L., Kunz, C., Rudderman, R., Buitrago-Téllez, C. H., Frodel, J., & Prein, J. (2014). The Comprehensive AOCMF Classification System: Mandible Fractures- Level 2 Tutorial. *Cranio-maxillofacial trauma & reconstruction*, issue 7, vol. 1, pp. 15-30.
DOI: 10.1055/s-0034-1389557
- [24]. Cornelius, C. P., Audigé, L., Kunz, C., Rudderman, R., Buitrago-Téllez, C. H., Frodel, J., & Prein, J. (2014). The Comprehensive AOCMF Classification System: Mandible Fractures-Level 3 Tutorial. *Cranio-maxillofacial trauma & reconstruction*, issue 7, vol. 1, pp. 31-43.
DOI: 10.1055/s-0034-1389558
- [25]. Viano, D. C., Bir, C., Walilko, T., & Sherman, D. (2004). Ballistic impact to the forehead, zygoma, and mandible: comparison of human and frangible dummy face biomechanics. *The Journal of trauma*, issue 156, vol. 6, pp. 1305-1311.
DOI: 10.1097/01.ta.0000064209.21216.4e
- [26]. Craig, M., Bir, C., Viano, D., & Tashman, S. (2008). Biomechanical response of the human mandible to impacts of the chin. *Journal of biomechanics*, issue 141, vol. 14, pp. 2972-2980.
DOI: 10.1016/j.jbiomech.2008.07.020
- [27]. Zhou, H., Lv, K., Yang, R., Li, Z., & Li, Z. (2016). Mechanics in the Production of Mandibular Fractures: A Clinical, Retrospective Case-Control Study. *PloS one*, issue 11, vol. 2, p. 0149553.
DOI: 10.1371/journal.pone.0149553.

